

## Nutritional management in stevens johnson syndrome

Edwina Raj<sup>1,\*</sup>, Chetan Gingeri<sup>2</sup>, Aruna Devi<sup>3</sup>, Qurathulain<sup>4</sup>

<sup>1</sup>Senior Dietitian, <sup>2</sup>Paediatrician, <sup>3</sup>Dietitian, <sup>4</sup>Trainee Dietitian, <sup>1,3,4</sup>Department of Clinical Nutrition and Dietetics, <sup>2</sup>Department of Pediatric Intensive Care Unit, Aster CMI Hospital, Bengaluru, Karnataka, India

**\*Corresponding Author: Edwina Raj**

Email: edwina.raj@asterhospital.com

---

### Abstract

Steven Johnson syndrome also known as Toxic Epidermal Necrolysis (Ten) is a severe hypersensitivity reaction which not only involves the skin but the mucosal membrane as well. This disease is caused due to sulphur drugs, antiepileptics, and antibiotics. This case report of a 5 year old boy who was admitted with general symptoms like cough, fever, rash and redness of the eyes with worsening of the symptoms. The medical treatment or procedures done at the hospital were (1) Amniotic Membrane Graft/ Amniotic Membrane Transplantation and (2) Collagen Dressing for the skin. Nutrition plays an important role for the growth, development, mucosal healing and faster recovery of the patient. The Purpose of effective nutrition management in SJS is to promote wound healing, positive nitrogen balance, weight preservation, immune function, and host defense mechanisms which is necessary for survival and prevent malnutrition. SJS is a highly catabolic state which requires an increase in dietary calorie and protein intake, in SJS only oral intake is not sufficient due to the damage of the oral mucosal membrane hence enteral nutrition is mandatory where supplements are given to meet the daily dietary requirements, the supplement provided to the patient was semi elemental to meet the requirements, for faster growth, repair and recovery.

**Keywords:** Stevens johnson syndrome, Nutrition in toxic epidermal necrolysis, Enteral nutrition, Partially hydrolysed semielemental formula.

---

### Methodology

This case study examines the nutritional intervention for the purpose of effective nutrition management in SJS (Steven Johnson Syndrome) for a 5 year old boy with a mode of enteral tube feeding due to oral mucositis.

Child was presented with cough since 2 days fever since 1 day rash since 1 day redness of eyes since 1 day and cough since 2 days, dry cough non productive for which child was on oral medications with fever since 1 day high grade intermittent not associated with chills and rigors, maculopapular rash started from neck and spread to face, trunk and extremities associated with itching and redness of eyes since 1 day associated with purulent eye discharge. Medication history: Child had received oral amoxclav and cough syrup prior to admission Past History: no significant family history / birth history. Development; appropriate for age. For the above mentioned complaints child was following up in other hospital, In view of worsening of symptoms child was referred to us for further care.

### Clinical Examination

Child had toxic appearance, sick looking, maculopapular rash over face, trunk and extremities and fluid filled vesicles over right side on chest with oral mucosa congestion. High grade of fever and irritability.

### Nutrition care plan and intervention

The aim was to achieve effective nutrition management in SJS (Steven Johnson Syndrome) for a 5 year old boy with prolonged oral mucositis to minimise ICU (Intensive Care Unit) and stress induced protein energy wasting. The child was started on nasogastric tube feeding with a choice of polymeric formula but due to intolerance the formula was replaced with partially hydrolysed semi elemental formula and was continued till discharge and reassessment was carried out regularly to record the nutritional status of the child.

On day 1- Enteral feed upto 20 ml / hour of polymeric feed was provided but due to intolerance (vomiting and loose stools), the feed was changed to 50ml/hr of semi-elemental feed was prescribed which was adequate.

Calories were increased as per tolerance of the patient. On day 4 - calorie and protein intake was increased (calories increased to: 1099 kcal, 34 g protein / day with calorie density - 1.0 kcal / ml.)

On the 6<sup>th</sup> Day along with regular feed salt was incorporated (Salt - 4 g / day) due to hyponatremia.

By the end of the 2<sup>nd</sup> week (14<sup>th</sup> day) nutritional rehabilitation was initiated with both oral soft diet and tube feed which was two weeks before the child's planned discharge.

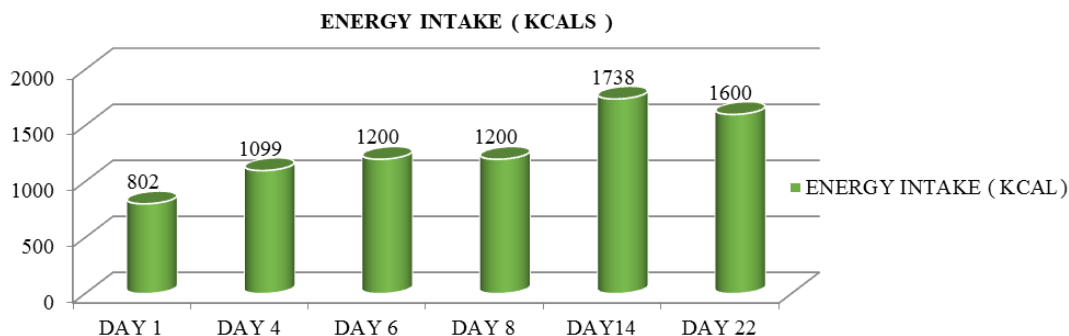


Fig. 1: calorie intake.

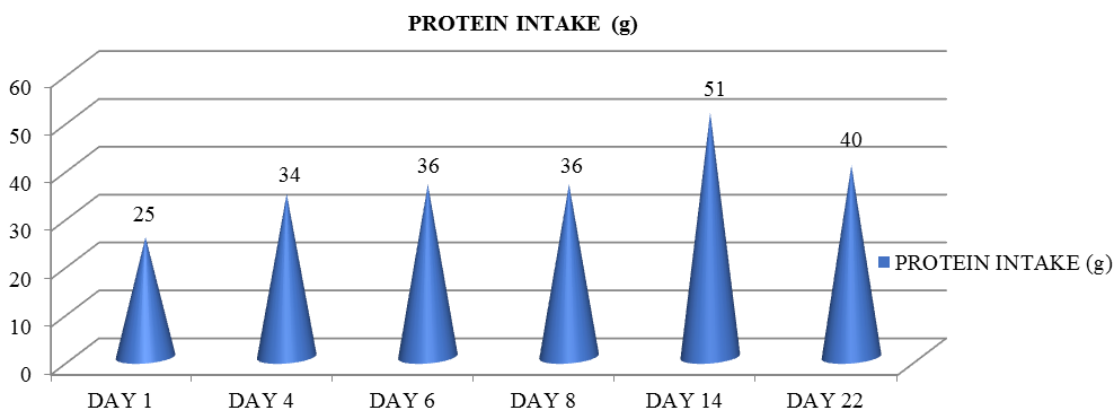


Fig. 2: protein intake.

Sample 1: Diet given to the patient name: XY AGE:5yr /Male Requirement:1750 kcal (116kcal/kg body weight), 51 g protein (3.4g/kg/day), Sodium- < 1900mg

Table 1: Pedia gold plus to semielemental formula.

Day	NG feeds/ oral feed.	Tolerance	Nutrition supplement	Mct Oil	Calorie Requirement (KCAL)	Protein Requirement (g)	Calorie Prescribed (KCAL)	Protein Prescribed (g)	Calorie Density kcal/ml
Day1	NG feeds 20-50ml/hr	no	Polymeric formula	-	1300	25	802	25	0.8
Day4	NG feed 100ml/2nd hrly	Improved	Semi-elemental	5 ml/day	1400	30	1099	34	1.0
Day6	NG feed 80 ml/2nd hrly	Good	Pedia Gold Plus	7.5 ml/day	1500	35	1200	36	1.3
Day8	NG feed 100 ml/2nd hrly	Good	Pedia Gold Plus	7.5 ml/day	1500	35	1200	36	1.0
Day 14	NG feed & oral intake (500 KCAL)	Good	Pedia Gold Plus	7.5 ml/day	1500	35	1750	51	-
Day 22 -	NG feed & oral intake (500 KCAL)	Good	Pedia Gold Plus	7.5 ml/day	1600-1700	40-50	1750	51	-

**Conclusion**

The case report explains a detailed nutritional management of a male child with Stevens Johnson Syndrome and toxic epidermal Necrolysis which increases the child’s nutritional requirement similar to that of burns case. The child before discharge regained his weight which was 15kg (between 10<sup>th</sup> to 25<sup>th</sup> centile for age) at the time of

admission. The patient was discharged after the diet counselling with prescribed calories 1750 kcal and 50 g of protein.

**Conflicts of Interest:** None.

**References**

1. "Stevens-Johnson syndrome". GARD. Archived from the original on 28 August 2016. Retrieved 26 August 2016.

2. "Stevens-Johnson syndrome/toxic epidermal necrolysis". Genetics Home Reference. July 2015. Archived from the original on 27 April 2017. Retrieved 26 April 2017.
3. "Orphanet: Toxic epidermal necrolysis". Orphanet. November 2008. Archived from the original on 27 April 2017. Retrieved 26 April 2017.
4. Lerch M, Mainetti C, Terziroli Beretta-Piccoli B, Harr T (2017). "Current Perspectives on Stevens-Johnson Syndrome and Toxic Epidermal Necrolysis". *Clin Rev Allergy Immunol* doi:10.1007/s12016-017-8654-z. PMID 29188475.
5. Hyzy, Robert C. (2017). Evidence-Based Critical Care: A Case Study Approach. Springer. p. 761. ISBN 9783319433417.
6. Adler NR, Aung AK, Ergen EN, Trubiano J, Goh MS, Phillips EJ. et al. "Recent advances in the understanding of severe cutaneous adverse reactions". *Br J Dermatol* 2017;177(5):1234–1247. doi:10.1111/bjd.15423. PMID 28256714.
7. Schwartz, RA; McDonough, PH; Lee, BW (August 2013). "Toxic epidermal necrolysis: Part I. Introduction, history, classification, clinical features, systemic manifestations, etiology, and immunopathogenesis". *J Am Academy Dermatol* 69(2):173.e1–13, quiz 185–6. doi:10.1016/j.jaad.2013.05.003. PMID 23866878.
8. Maverakis, Emanuel, Wang, Elizabeth A.; Shinkai, Kanade; et al. "Stevens-Johnson Syndrome and Toxic Epidermal Necrolysis Standard Reporting and Evaluation Guidelines". *JAMA Dermatol* doi:10.1001/jamadermatol.2017.0160.
9. Tigchelaar, H.; Kannikeswaran, N.; Kamat, D. (December 2008). "Stevens–Johnson Syndrome: An intriguing diagnosis". *pediatricsconsultantlive.com*. UBM Medica. Archived from the original on 17 August 2012. (Registration required (help)).
10. Mockenhaupt M. "The current understanding of Stevens–Johnson syndrome and toxic epidermal necrolysis". *Expert Rev Clin Immunol* 2011;7(6):803–815. doi:10.1586/eci.11.66. PMID 22014021.
11. Teraki Y, Shibuya M, Izaki S; Shibuya; Izaki. "Stevens-Johnson syndrome and toxic epidermal necrolysis due to anticonvulsants share certain clinical and laboratory features with drug-induced hypersensitivity syndrome, despite differences in cutaneous presentations". *Clin Exp Dermatol* 2010;35(7):723–728. doi:10.1111/j.1365-2230.2009.03718.x. PMID 19874350.
12. Cooper KL. "Drug reaction, skin care, skin loss". *Crit Care Nurse* 2012;32(4):52–59. doi:10.4037/ccn2012340. PMID 22855079.

**How to cite this article:** Raj E, Gingeri C, Devi A, Qurathulain, Nutritional management in stevens johnson syndrome. *J Nutr, Metab Health Sci*, 2019;2(1):20-22