



Review Article

A clinical case study and medical nutritional therapy in pediatric meningoencephalitis

Edwina Raj^{1,*}, C P Ravi Kumar², Arunadevi J¹, Rebecca Renee Joseph¹, Chetan Ginigeri³

¹Dept. of Clinical Nutrition and Dietetics, Aster CMI Hospital, Bengaluru, Karnataka, India

²Dept. of Paediatric Neurology, Aster CMI Hospital, Bengaluru, Karnataka, India

³Dept. of Paediatric, Aster CMI Hospital, Bengaluru, Karnataka, India



ARTICLE INFO

Article history:

Received 13-08-2020

Accepted 23-09-2020

Available online 28-10-2020

Keywords:

Pediatric Meningoencephalitis

Viral Encephalitis

Nasogastric feeding

Human herpesvirus

Medical Nutrition Therapy in

Meningoencephalitis

ABSTRACT

Meningoencephalitis is an inflammation of the brain and its surrounding protective membranes. Meningitis is a life-threatening disease and can lead to significant sequelae. We were presented with a 6 year 5 months old female child on ventilation, retrieved by referral hospital on examination revealed human herpesvirus 6 through cerebrospinal fluid analysis and diagnosed with meningoencephalitis on Magnetic Resonance Imaging(MRI) with three repeated failed extubation and hence planned tracheostomy. Child presented no movements with suspected motor or sensory (vision, hearing) disability, generalized tonic-clonic seizure (GTCS), altered sensorium requiring a long term rehabilitation and nutrition support. On close monitoring, a continuous effort of three months and with a multidisciplinary clinical approach from different disciplines including neurologist, intensivist, clinical dietitian and physiotherapy, the child successfully completed the long term rehabilitation treatment with remarkable improvement observed within 12 weeks both neurologically and nutritionally with a better clinical outcome.

© 2020 Published by Innovative Publication. This is an open access article under the CC BY-NC license (<https://creativecommons.org/licenses/by-nc/4.0/>)

1. Introduction

Meningoencephalitis can be caused by bacteria, viruses, fungi, and protozoan or as secondary sequel of other inflammations like AIDS. The inflammation causes the brain to swell leading to confusion, changes in alertness, and seizures. In general, meningoencephalitis and encephalitis represent uncommon responses to common infections. Most infected patients have a mild syndrome of meningoencephalitis rather than severe encephalitis.¹ Viral encephalitis also includes slow viral and chronic degenerative diseases of presumed viral origin.² Correct immediate diagnosis and introduction of symptomatic and specific therapy has a dramatic influence upon survival and reduces the extent of permanent brain injury. Viruses are predominant causes of infectious encephalitis. Viral encephalitis is a medical emergency and its prognosis

depends on the kind of causative pathogen and immune status of the patient. Herpes simplex virus (HSV) is the most prevalent cause of viral encephalitis in the developed countries with the annual incidence rate of 1/250,000 -500,000 people. In viral encephalitis, the virus first enters the body and then replicates in local or regional tissues, such as gastrointestinal tract, skin, urogenital, or respiratory system. Subsequent dissemination in the central nervous system occurs through hematogenic routes (enterovirus, arbovirus, HSV, HIV, mumps) or through retrograde transportation via axons, such as in the case of herpes virus, rabies virus, or prion protein. Most of the guidelines cited focal neurological signs, seizures, fever, altered levels of consciousness (ALOC) and changes to personality or behaviour as signs and symptoms of encephalitis in both children and adults.³

* Corresponding author.

E-mail address: edwina.raj@asterhospital.com (E. Raj).

2. Materials and Methods

A 6yr 5m old female was retrieved from another hospital with ET tube insitu. Child developed fever 7days back which was high grade not associated with chills and rigors, decreasing on medication temporarily. Child complained of headache more in the frontal region and no diurnal variation. Child had decreased appetite since the beginning of fever and since last 2 days was taking only liquids. On 6th day of fever child became drowsy and hence was taken to hospital and was admitted. Child developed convulsions on the same day in the form of GTCS which was aborted with Midazolam. Child was started on Levetiracetam. On the same day child was intubated in v/o poor GCS. LP was done in the hospital which showed predominant polymorphs and so child was started on Magnex (Cefoperazone + Sulbactam), Acyclovir. MRI was done which was suggestive of meningoencephalitis and child was started on steroids. HSV PCR, Blood culture and CSF culture were sent and reports awaited. Child was referred to our hospital for further management.

2.1. Physical Examination

On physical examination, general physical findings should be noted including heart rate, respiratory rate, blood pressure, presence or absence of meningismus, and signs of involvement of other systems, particularly skin rashes and lymph nodes, as well as signs of trauma. Fundoscopic examination including indirect ophthalmoscopy may elucidate vasculitis and also, the shaken baby syndrome in case of non-traumatic injury. Neurological findings depend on which part of the brain is primarily involved. Findings may predominate in any part of the brain or non - CNS sites may predominate.

2.2. Past History

Child had episode of fever in the first week of February which subsided after taking medications. Child had another episode of fever two weeks back which lasted for 4 days and then subsided. Child was active during the fever free period.

2.3. Birth History

Full term child of Normal delivery. Birth weight was 2.6kg. No History of NICU stay. Child has been vaccinated up - to the age of 3 years.

2.4. Family History

Patient is the second child of non-consanguineous marriage. Child has one elder and one younger sibling. No history of similar complaints in the family

2.5. Case details

2.5.1. Vitals

HR-80/min

Spo2- 98% with 80% Fio2

BP- 102/60 mm hg

PP- well felt and warm

2.5.2. Physical Examination

1. Height: Unable to stand (confined to bed & ventilated)
2. Weight for Age on admission- 13.6kg (on 3rd centile)
3. Weight for age on follow up after 3 weeks- 17.5kg (between 10th to 25th centile)
4. Mid upper arm circumference on last follow up – 13.5cm

2.6. Treatment Plan

On day one, child was on mechanical ventilation with ICD insertion. EEG was conducted which showed slowing of waves (probable encephalopathy). Medications such as Ceftriaxone, Acyclovir and azithromycin were introduced. Neuro-protection and anti-edema measures were taken. Sedation was optimised and neurologist opinion was given. Patient wasn't given anything orally. ECHO procedure was done which showed normal

On day two, ceftiaxone drug was continued along with NG feeds and IV fluids were tapered down. Sodium levels were monitored upto levels 135-145 and 3% Nacl was tapered down accordingly and NG feeds were initiated. Patient had altered sensorium

On day three, sedation was stopped and sensorium was reassessed. She developed tonic posturing, hence sedation was restarted. Polyuria was present so was decided to be replaced with NS if hemodynamic instability was seen.

On day four, tonic posturing was still present with polyuria, right sided pneumothorax was observed which resolved. A trial of CPAP was given but the child did not tolerate more than 15 min hence it was changed back to Control mode. CSF analysis was done which showed normal protein sugars, differential count of all lymphocytes and Human Herpes virus 6 was detected. Extubation was attempted for the past 3 days, without success. Child had needed long term rehabilitation, hence Tracheostomy was planned. Child did not show any movements, which meant that there would be a motor or sensory (vision, hearing) disability. Child's parents were counselled regarding the need for ventilation and tracheostomy. Child was opening eyes spontaneously with no eye contact. Ophthalmic examination was done which showed normal.

On day five, child was seen to be holding on without ventilation but however intubation and tracheostomy was required to be considered. Child did need long term rehabilitation and support as she was critically ill. Child was extubated with spontaneous breathing trial (SBT) Trial and

Table 1: Clinical Parameters

Electrolytes	14.3.20	16.3.20	17.3.20
Sodium (mg)	141	139	143
Potassium(mg)	3.35	4.0	4.0
Urea(mg)		21	-
Haemoglobin(g)	9.3	-	9.7
Magnesium (mg) Normal range (1.7-2.3)	1.6mg		1.7

Dexamethasone 4mg was given.

On day six, sensorium still remained poor however, polyurea was better and pneumothorax was resolved. Right ICD was placed and on removal lungs showed good expansion on the right side. Child was on HFNC with stable hemodynamics, Airway maintained breathing pattern and showed improvement, blood gas was normal with good oxygenation but sensorium remained poor, with no focus and lifting limbs against gravity.

1. On day seven, Air mattress was used and the child's position was changed every four hours with help of physiotherapy. Child was maintaining saturation in room air with no respiratory distress. Central Nervous System showed better eye focusing, paxitane drug was initiated and levetiracetam was given orally. On day ten, the patient was mobilized, antibiotics and NG feed were continued along with multivitamins, calcium and patient was shifted to ward. HNFC was discontinued with intermittent focusing and posturing episodes appeared to be less. Child was still on NG feeds and was discharged after training mother on NG feeds and physiotherapy. On discharge she was hemodynamically stable, but had neurological sequela meaning she was unable to recognize or make eye contact, not able to move against gravity. She required a long term physiotherapy and nutritional rehabilitation. Child's prognosis was unpredictable. However on OPD visit patient still had issues with posturing after a week but tolerated NG feeds.

2.7. Nutrition Care Plan

Day one the child was nil per oral, thereby nasogastric feed was initiated within 24 hours and IV fluids were tapered. A polymeric formula was provided as trickle feed but replaced with partially hydrolysed formula after 3 days due to feed intolerance.⁴ A peptide based semi- elemental formula was prescribed at the rate of 10 ml 2nd hrly thereby full fluids was targeted by day 6 due to a potential risk of refeeding since the child had history of poor oral intake since one week, underweight and low levels of potassium, magnesium was observed.

2.7.1. Nutrition assessment

1. Subjective Global Assessment grade- C

2. Weight for age on admission 13.5kg – on 3rd centile (underweight).

2.7.2. Nutritional challenges

1. Underweight for age with high risk of refeeding syndrome:⁵ poor oral intake since 1 week, was only on oral liquid & hypokalemia on admission was noted.
2. Feed intolerance; on starting trickle feeds (standard polymeric formula)
3. Route: nasogastric feeding tube until discharge with no improvements neurologically observed for 9 days.
4. Poor socioeconomic status and lack of awareness of importance of macro nutrients among the family.
5. Mother had the burden of taking care of two other siblings and manage the family, therefore less importance was given to this child.

2.7.3. Nutrient requirement in PICU:

Energy (kcal): 802 kcal/day (WHO equation⁵)

Protein(g): 24.3g /day (1.8g/kg/day)

Fat(g): 40% of total energy prescribed

Carbohydrate(g): 50% of total energy prescribed

Fluid requirement (ml):1175ml

2.7.4. Nutrient requirement when shifted to ward:

Energy (kcal): 75kcal/kg/day (RDA) - modified RDA: 85kcal/kg/day (1147kcal/day)

Protein(g): 1.1g/kg/day (RDA)-modified RDA 2g /day (27g/day)

Fat (g): 35% of total energy prescribed

Carbohydrate (g): 55% of total energy prescribed

Fluid requirement (ml):1175ml

On follow up-1 at OPD – after 4 weeks of discharge

Home recall: followed as prescribed & requested for blenderised home based feed preparation

Route- Nasogastric feeding tube + Oral feeds attempted (pureed, calorie dense feed thrice /day)

2.7.5. Supplement: continued the same supplement as tolerated earlier by the child

Composition of home based feed: nuts, oilseeds, dry-fruit, meat broth, vegetables, fruit, turmeric, pepper, coconut oil, olive oil

On Follow up 2 at OPD: after 8 weeks of discharge

Table 2: Medication

Type of medicine	Dosage	Role of medicine
INJ ACYCLOVIR 300mg	IV thrice a day for 5 days	Antiviral drug- treats infections caused by the herpes viruses
Syp levipill [100mg/ml]	2ml NG twice a day	anti-epileptic medicine used to treat seizures
Tab pacitane 2mg	Morning and afternoon via NG	to treat severe movement side effects
Syp seven seas 5ml	NG twice a day for 1 month	vitamin rich Cod Liver Oil, a natural source of Omega 3 fatty acids (DHA and EPA) and Vitamins A and D
Calcitriol sachet	For 6 weeks 1 sachet once a week	Active form of Vit D

Table 3:

Day 5-6Route: Nasogastric feed in Paediatric Intensive Care Unit (PICU)**Rate of infusion:** 80ml/2nd hrly + Intravenous fluid 5% dextrose at 10ml/hr **Type of formula:** partially hydrolysed semi elemental formula

Energy(kcal)	Protein(g)	Fat(g)	Carbohydrate(g)	Total Volume	Calorie density
900	25	44	110	960ml	1.0kcal/ml

Table 4:

DAY 8-9 at ward Route: Nasogastric feeding tube in Paediatric Intensive Care Unit(PICU)**Rate of infusion:** 100ml/2nd hrly + IV fluid withdrawn **Type of feed:** partially hydrolysed semi elemental formula

Energy(kcal)	Protein(g)	Fat(g)	Carbohydrate(g)	Total Volume	Calorie density
1150	28	48	150	1200ml	0.95kcal/ml

Table 5: Nutrition Care Plan

Type of feed	Energy(kcal)	Protein(g)	Fat(g)	CHO(g)	Na(mg)	K(mg)	Calorie density/ml	Total volume
Supplement	760	24	29.6	100.8	160	218.4	-	-
Blenderised feed	350	4	20	30	600	100	-	-
Total amount	1110	28	49	131	760	318	1.0	1100

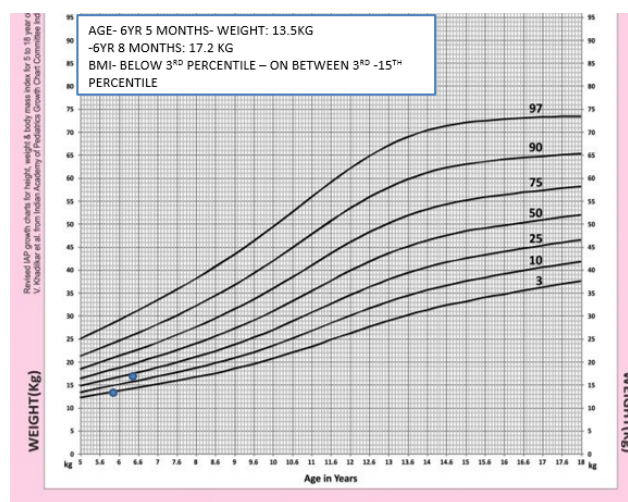
Home recall: 900kcal, 20g of protein, reduced supplement due to cost constraint and included majority of fruit based feed

2.7.6. Nutrition Care Plan

1. Counselling the importance of macronutrient requirement
2. Revised plan, provided pureed recipes.
3. Cost effective supplement made available to increase compliance to medical nutrition therapy to catch up child's growth & development.

2.7.7. On Follow up -3; on teleconsultation

1. Child was provided soft food and liquids orally.
2. Stopped NG feed
3. Child's appetite improved
4. Weight for age achieved at 10th to 25th centile (17.2kg). Height: 113cm between 25th to 50th centile. Mid upper arm circumference on last follow up – 13.5cm (normal).
5. Child's gait and speech normal, chewing and swallowing food, social, intellectual and cognitive improvement observed.

**Fig. 1:**

3. Result and Conclusion

A paediatric case of meningoencephalitis, detected with human herpesvirus 6 and an episode of seizure, the child was retrieved and ventilated at pediatric intensive

care unit with repeated failed extubation, poor prognosis, underweight on admission, with high risk of refeeding syndrome, altered sensorium. Initially there was no signs of improvement observed neurologically (unable to recognize or make eye contact, not able to move against gravity) in first two weeks at the onset of disease and continued on nasogastric tube on discharge. The child was regularly followed up with pediatric neurologist, nutritionist and physiotherapist to ensure the child's catch up growth and development is attained, to prevent growth faltering and protein energy wasting. The medical nutrition therapy involved fine tuning of child's nutrition care plan based on the nutritional challenges, with regular monitoring we were able to observe successful clinical outcome in the child with an improvement in weight, transition to oral feed and normal neurological development was observed.

4. Source of Funding

None.

5. Conflict of Interest

None.

References

1. Study of acute viral meningoencephalitis in children in sub-himalayan tarai region: clinico-epidemiological, etiological, and imaging profile. *Indian J Child Health*. 2015;2(4):177–81.
2. Kennedy PGE. Viral encephalitis: causes, differential diagnosis, and management. *Journal of Neurology, Neurosurgery and Psychiatry*; 2015.
3. Steiner I, Budka H, Chaudhuri A. Viral meningoencephalitis: A review of diagnostic methods and guidelines for management. *Eur J Neurol*;17(8):999–e57.
4. Goday PS, Mehta NM, Lee JH. Pediatric Critical Care Nutrition. *Asia Pac J Clin Nutr*. 2015;30(4):581.
5. Mehta NM, Skillman HE, Irving SY, Coss-Bu JA, Vermilyea S, Farrington EA, et al. Guidelines for the Provision and Assessment of Nutrition Support Therapy in the Pediatric Critically Ill Patient: Society of Critical Care Medicine and American Society for Parenteral and Enteral Nutrition. *JPEN J Parenter Enteral Nutr*. 2017;41(5):706–42.

Author biography

Edwina Raj Senior Dietitian

C P Ravi Kumar Consultant

Arunadevi J Dietitian

Rebecca Renee Joseph Dietitian

Chetan Ginigeri Consultant

Cite this article: Raj E, Kumar CPR, Arunadevi J, Joseph RR, Ginigeri C. **A clinical case study and medical nutritional therapy in pediatric meningoencephalitis.** *IP J Nutr Metab Health Sci* 2020;3(3):85-89.